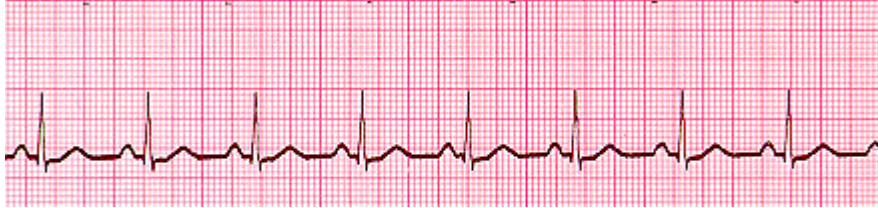



## ECG Rhythm Study Guide

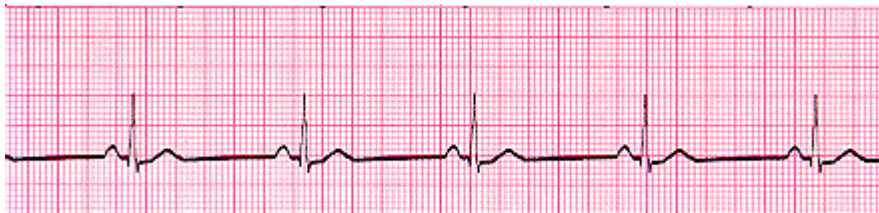### Normal Sinus Rhythm



Looking at the ECG you'll see that:

- Rhythm - Regular
- Rate - (60-100 bpm)
- QRS Duration - Normal
- P Wave - Visible before each QRS complex
- P-R Interval - Normal (<5 small Squares. Anything above and this would be 1st degree block)
- Indicates that the electrical signal is generated by the sinus node and travelling in a normal fashion in the heart.

### Sinus Bradycardia

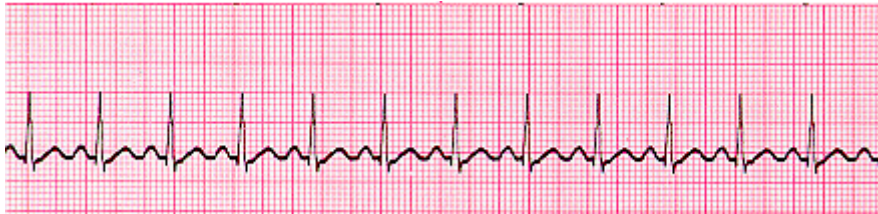

A heart rate less than 60 beats per minute (BPM). This in a healthy athletic person may be 'normal', but other causes may be due to increased vagal tone from drug abuse, hypoglycemia and brain injury with increase intracranial pressure (ICP) as examples  
Looking at the ECG you'll see that:

- Rhythm - Regular
- Rate - less than 60 beats per minute
- QRS Duration - Normal
- P Wave - Visible before each QRS complex
- P-R Interval - Normal
- Usually benign and often caused by patients on beta blockers



## Sinus Tachycardia

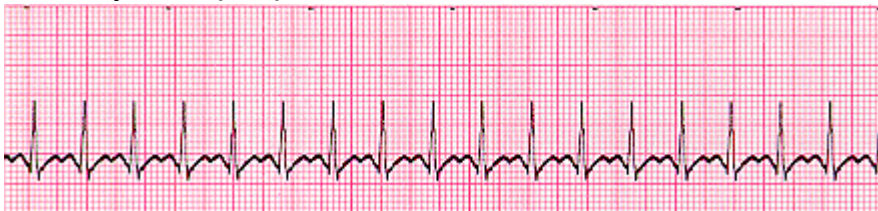

An excessive heart rate above 100 beats per minute (BPM) which originates from the SA node. Causes include stress, fright, illness and exercise. Not usually a surprise if it is triggered in response to regulatory changes e.g. shock. But if there is no apparent trigger then medications may be required to suppress the rhythm

Looking at the ECG you'll see that:

- Rhythm - Regular
- Rate - More than 100 beats per minute
- QRS Duration - Normal
- P Wave - Visible before each QRS complex
- P-R Interval - Normal
- The impulse generating the heart beats are normal, but they are occurring at a faster pace than normal. Seen during exercise

## Supraventricular Tachycardia (SVT) Abnormal



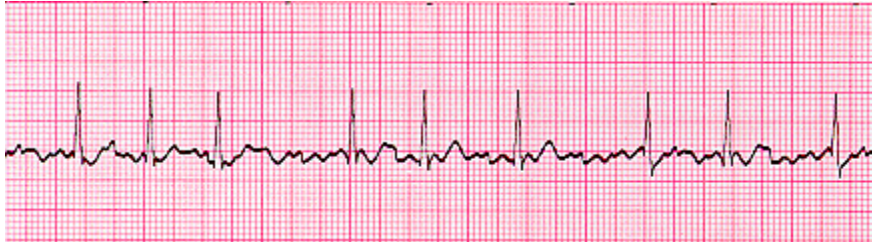A narrow complex tachycardia or atrial tachycardia which originates in the 'atria' but is not under direct control from the SA node. SVT can occur in all age groups

Looking at the ECG you'll see that:

- Rhythm - Regular
- Rate - 140-220 beats per minute
- QRS Duration - Usually normal
- P Wave - Often buried in preceding T wave
- P-R Interval - Depends on site of supraventricular pacemaker
- Impulses stimulating the heart are not being generated by the sinus node, but instead are coming from a collection of tissue around and involving the atrioventricular (AV) node



## Atrial Fibrillation

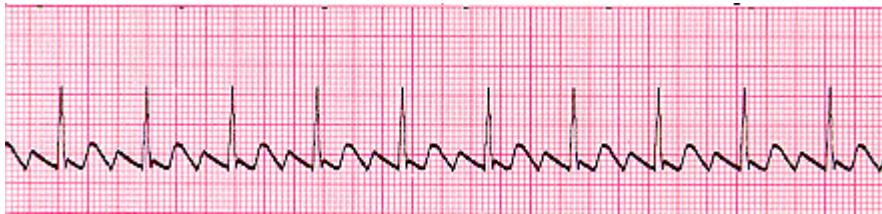

Many sites within the atria are generating their own electrical impulses, leading to irregular conduction of impulses to the ventricles that generate the heartbeat. This irregular rhythm can be felt when palpating a pulse

Looking at the ECG you'll see that:

- Rhythm - Irregularly irregular
- Rate - usually 100-160 beats per minute but slower if on medication
- QRS Duration - Usually normal
- P Wave - Not distinguishable as the atria are firing off all over
- P-R Interval - Not measurable
- The atria fire electrical impulses in an irregular fashion causing irregular heart rhythm

## Atrial Flutter

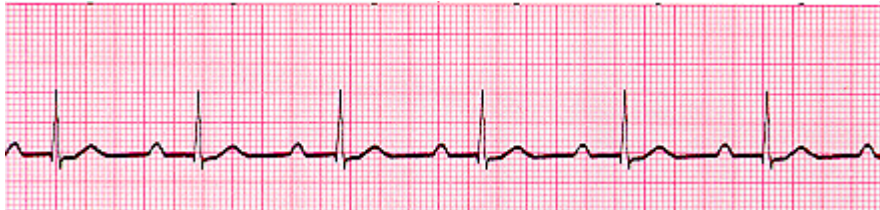

Looking at the ECG you'll see that:

- Rhythm - Regular
- Rate - Around 110 beats per minute
- QRS Duration - Usually normal
- P Wave - Replaced with multiple F (flutter) waves, usually at a ratio of 2:1 (2F - 1QRS) but sometimes 3:1
- P Wave rate - 300 beats per minute
- P-R Interval - Not measurable
- As with SVT the abnormal tissue generating the rapid heart rate is also in the atria, however, the atrioventricular node is not involved in this case.



## 1st Degree AV Block

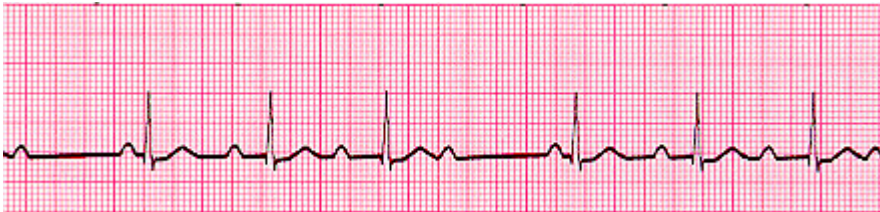

1st Degree AV block is caused by a conduction delay through the AV node but all electrical signals reach the ventricles. This rarely causes any problems by itself and often trained athletes can be seen to have it. The normal P-R interval is between 0.12s to 0.20s in length, or 3-5 small squares on the ECG.

Looking at the ECG you'll see that:

- Rhythm - Regular
- Rate - Normal
- QRS Duration - Normal
- P Wave - Ratio 1:1
- P Wave rate - Normal
- P-R Interval - Prolonged (>5 small squares)

## 2nd Degree Block Type 1 (Wenckebach)



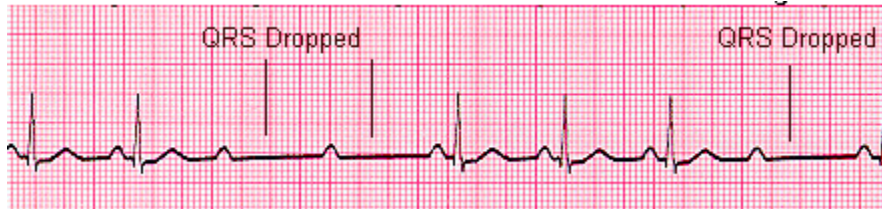Another condition whereby a conduction block of some, but not all atrial beats getting through to the ventricles. There is progressive lengthening of the PR interval and then failure of conduction of an atrial beat, this is seen by a dropped QRS complex.

Looking at the ECG you'll see that:

- Rhythm - Regularly irregular
- Rate - Normal or Slow
- QRS Duration - Normal
- P Wave - Ratio 1:1 for 2,3 or 4 cycles then 1:0.
- P Wave rate - Normal but faster than QRS rate
- P-R Interval - Progressive lengthening of P-R interval until a QRS complex is dropped



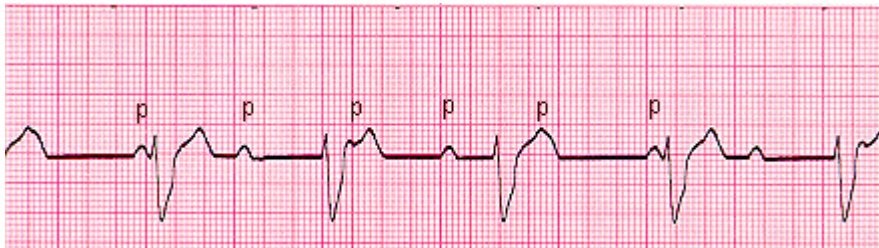
## 2nd Degree Block Type 2



When electrical excitation sometimes fails to pass through the A-V node or bundle of His, this intermittent occurrence is said to be called second degree heart block. Electrical conduction usually has a constant P-R interval, in the case of type 2 block atrial contractions are not regularly followed by ventricular contraction. Looking at the ECG you'll see that:

- Rhythm - Regular
- Rate - Normal or Slow
- QRS Duration - Prolonged
- P Wave - Ratio 2:1, 3:1
- P Wave rate - Normal but faster than QRS rate
- P-R Interval - Normal or prolonged but constant

## 3rd Degree Block



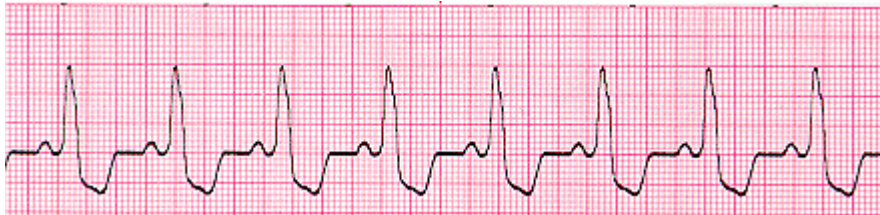3rd degree block or complete heart block occurs when atrial contractions are 'normal' but no electrical conduction is conveyed to the ventricles. The ventricles then generate their own signal through an 'escape mechanism' from a focus somewhere within the ventricle. The ventricular escape beats are usually 'slow'

Looking at the ECG you'll see that:

- Rhythm - Regular
- Rate - Slow
- QRS Duration - Prolonged
- P Wave - Unrelated
- P Wave rate - Normal but faster than QRS rate
- P-R Interval - Variation
- Complete AV block. No atrial impulses pass through the atrioventricular node and the ventricles generate their own rhythm



## Bundle Branch Block

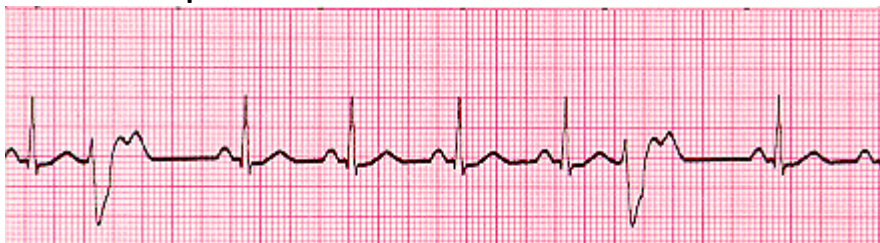

Abnormal conduction through the bundle branches will cause a depolarization delay through the ventricular muscle, this delay shows as a widening of the QRS complex. Right Bundle Branch Block (RBBB) indicates problems in the right side of the heart. Whereas Left Bundle Branch Block (LBBB) is an indication of heart disease. If LBBB is present then further interpretation of the ECG cannot be carried out.

Looking at the ECG you'll see that:

- Rhythm - Regular
- Rate - Normal
- QRS Duration - Prolonged
- P Wave - Ratio 1:1
- P Wave rate - Normal and same as QRS rate
- P-R Interval - Normal

## Premature Ventricular Complexes



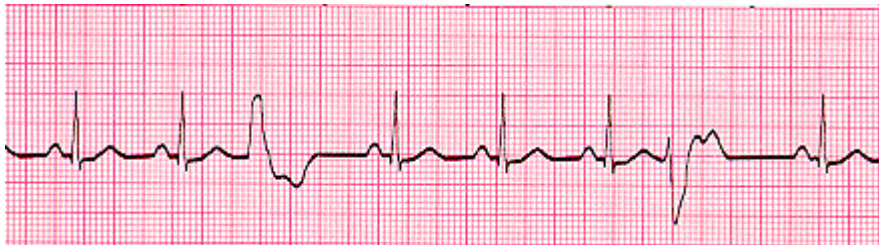Due to a part of the heart depolarizing earlier than it should

Looking at the ECG you'll see that:

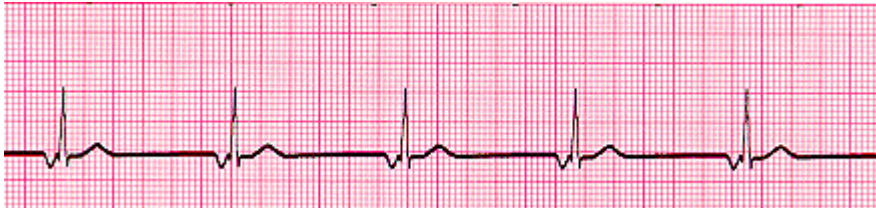- Rhythm - Regular
- Rate - Normal
- QRS Duration - Normal
- P Wave - Ratio 1:1
- P Wave rate - Normal and same as QRS rate
- P-R Interval - Normal



- Also you'll see 2 odd waveforms, these are the ventricles depolarizing prematurely in response to a signal within the ventricles. (Above - unifocal PVC's as they look alike if they differed in appearance they would be called multifocal PVC's, as below)



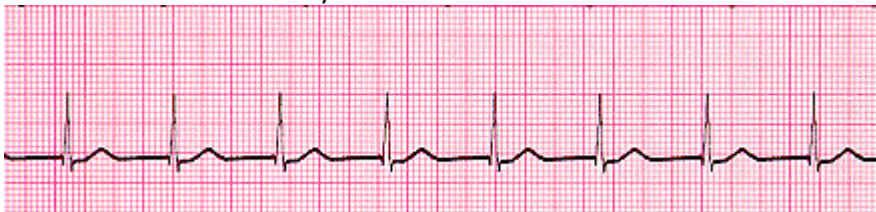### Junctional Rhythms



Looking at the ECG you'll see that:

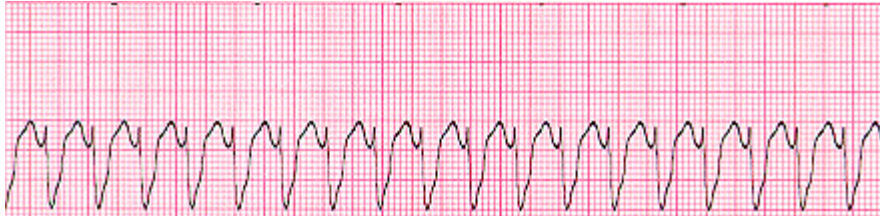- Rhythm - Regular
- Rate - 40-60 Beats per minute
- QRS Duration - Normal
- P Wave - Ratio 1:1 if visible. Inverted in lead II
- P Wave rate - Same as QRS rate
- P-R Interval - Variable

Below - Accelerated Junctional Rhythm





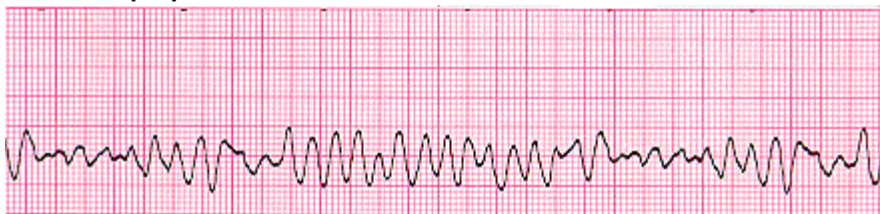### **Ventricular Tachycardia (VT) Abnormal**



Looking at the ECG you'll see that:

- Rhythm - Regular
- Rate - 180-190 Beats per minute
- QRS Duration - Prolonged
- P Wave - Not seen
- Results from abnormal tissues in the ventricles generating a rapid and irregular heart rhythm. Poor cardiac output is usually associated with this rhythm thus causing the pt to go into cardiac arrest. Shock this rhythm if the patient is unconscious and without a pulse

### **Ventricular Fibrillation (VF) Abnormal**



Disorganized electrical signals cause the ventricles to quiver instead of contract in a rhythmic fashion. A patient will be unconscious as blood is not pumped to the brain. Immediate treatment by defibrillation is indicated. This condition may occur during or after a myocardial infarct.

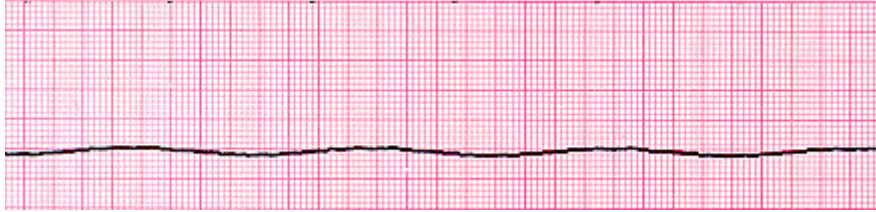
Looking at the ECG you'll see that:

- Rhythm - Irregular
- Rate - 300+, disorganized
- QRS Duration - Not recognizable
- P Wave - Not seen
- This patient needs to be defibrillated!! QUICKLY





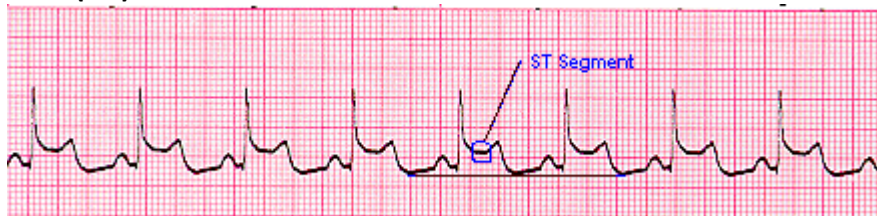### Asystole - Abnormal



Looking at the ECG you'll see that:

- Rhythm - Flat
- Rate - 0 Beats per minute
- QRS Duration - None
- P Wave - None
- Carry out CPR!!

### Myocardial Infarct (MI)



Looking at the ECG you'll see that:

- Rhythm - Regular